Investigation of Hunter-harvested Carcasses and Laboratory Trial to Understand the Potential Transmission of Pathogens from Poultry Litter to Wild Turkeys (*Meleagris gallopavo*)

Richard Gerhold and Michelle Nobrega
Biomedical and Diagnostic Sciences, College of Veterinary Medicine, University of Tennessee, Knoxville, TN
and
Roger Applegate,
Wildlife Biologist,
Tennessee Wildlife Resources Agency Wildlife and Forestry Division

TWRA Wildlife Technical Report 16-3

Equal opportunity to participate in and benefit from programs of the Tennessee Wildlife Resources Agency is available to all persons without regard to their race, color, national origin, sex, age, disability, or military service. TWRA is also an equal opportunity/equal access employer. Questions should be directed to TWRA, Human Resources Office, P.O. Box 40747, Nashville, TN 37204, (615) 781-6594 (TDD 781-6691), or to the U.S. Fish and Wildlife Service, Office for Human Resources, 4401 N. Fairfax Dr., Arlington, VA 22203.

Investigation of Hunter-harvested Carcasses and Laboratory Trial to Understand the Potential Transmission of Pathogens from Poultry Litter to Wild Turkeys (*Meleagris gallopavo*)

Richard Gerhold[1], Michelle Nobrega[1], and Roger Applegate[2]

[1]Biomedical and Diagnostic Sciences, College of Veterinary Medicine, University of Tennessee, Knoxville, TN

[2] Tennessee Wildlife Resources Agency

Summary: Two separate investigations were performed to establish data on the health of wild turkeys (*Meleagris gallopavo*) in a three county area in middle Tennessee where wild turkey numbers are perceived to be lower based on reduced harvest and anecdotal reports from hunters. The first investigation consisted of examining hunter-killed wild turkeys for gross and histological lesions in conjunction with serological and molecular testing for specific and targeted pathogens. Birds were collected from counties where turkey numbers are perceived to be lower (affected experimental counties) and counties where turkey numbers are perceived to have no appreciable changes (non-affected control counties). The second investigation involved a controlled laboratory study in which a commercial breed of wild turkeys was placed in floor pens containing either clean wood shavings (controls) or litter removed from a poultry breeder facility in Lawrence County, Tennessee.

During the 2014 and 2015 spring turkey seasons (~April-May), 106 and 112 hunter-killed wild turkeys were examined, respectively, for a total of 218 wild turkeys examined. Carcasses were collected from either experimental counties (Giles, Lawrence, Lincoln, and Wayne) where turkey harvest has declined or control counties where turkey harvest has not appreciably declined (Bedford, Lewis, and Maury). Carcasses were examined for gross lesions and, when available, samples collected for microscopic observation and serological (Enzyme Linked Immunosorbent Assay; ELISA) testing for avian influenza virus, New Castle Disease virus, and *Mycoplasma* spp. In total, 2 birds were ELISA-positive and one bird was inconclusive for avian influenza virus (AIV); 53 birds were ELISA-positive for New Castle disease virus (NCDV); and 16 birds were ELISA-positive for *Mycoplasma* spp. bacteria. The AI positive birds came from a control county; whereas the majority of the NCDV and *Mycoplasma* spp. positive birds came from the experimental counties. Important histological findings of hunter-killed turkeys from 2014 included enteritis, typhlitis (cecal inflammation), various granulomas within organs, and lymphoid hyperplasia from 8 (7.5%) birds; all from experimental counties. Histological lesions from 2015 hunter-killed turkeys included moderate to severe typhlitis in 75 (67%) of turkeys. Of these 75 birds with typhlitis, 45 (60%) were from experimental counties and 30 (40%) from control counties. In addition presumably incidental findings included mild to marked

bronchointerstitial pneumonia in three birds and focal pulmonary granulomas in two birds. Polymerase Chain Reaction (PCR) testing to amplify DNA followed by nucleotide sequencing was performed on cecal tissue from all hunter-killed turkeys with histological evidence of cecal lesions. The PCR primers targeted the protozoa *Histomonas meleagridis*, the causative agent of histomonosis (i.e. histomoniasis; blackhead). The PCR and sequence results indicated that three birds have evidence of *H. meleagridis* DNA; all positive birds were from experimental counties.

In the experimental infection bioassay trial involving poultry litter from the Lawrence county poultry facility, one of 24 of the experimental birds was euthanized on day 13 due to severe lethargy. Necropsy findings disclosed liver and cecal lesions consistent with *H. meleagridis* infection, which was confirmed by histological, parasite culture, and PCR testing. A second experimental bird with cecal lesions was PCR and sequence positive for *H. meleagridis*.

Collectively, our results suggest that *H. meleagridis* may be associated with poultry litter and may be a cause for concern for wild turkeys in this region; however, further research is needed before this connection can be confirmed. Further work on *H. meleagridis* prevalence, transmission dynamics, environmental persistence, and control measures is warranted. In particular we believe the laboratory bioassay study needs to be repeated at a larger scale to examine litter from multiple different poultry facilities from both within and outside the experimental counties. In addition, the litter from these various poultry facilities, as well as the litter from the poultry facility used in this study, should be screened for various parasitic eggs and the arthropods within the litter examined for the presence of *H. meleagridis* DNA via PCR and sequencing. Although serological evidence of AIV, NCDV, and *Mycoplasma* spp. were observed on ELISA testing of hunter-killed birds, no histological lesions were observed, thus it is unlikely the turkeys had any detrimental effects from the pathogens; potentially due to a non-pathogenic strain or that the immune system of these birds successfully controlled the infection(s). All of the experimental and control turkeys in the laboratory study were seronegative for AIV, NCDV, and *Mycoplasma* spp. using sera collected at the termination of the study. Finally, we are in the process of constructing a serological ELISA test for *H. meleagridis* which will likely be more sensitive than PCR testing, especially in early infections. Once constructed, serum from hunter-killed and litter study turkeys should be analyzed with the ELISA test to determine if further birds have antibodies to *H. meleagridis*.

Introduction: There have been concerns expressed by the public that wild turkey populations in the lower three middle Tennessee Counties consisting of Wayne, Lawrence, and Giles (experimental counties) are less abundant than previously. Although multiple factors could be responsible for this phenomenon, it is important that diseases be given consideration. Several diseases have potential population implications including avian poxvirus, histomonosis (i.e. histomoniasis; blackhead), and *Mycoplasma* sp. (Davidson et al., 1985)

Avian poxvirus associated lesions consist of multiple to coalescing skin (dry pox) and/or oral cavity (wet pox) firm, dark, variable-sized nodules that can obscure vision, and occlude the oral cavity leading to respiratory or esophageal blockage (Davidson et al, 1985; Forrester and Spalding, 2003). Pox can be transmitted by *Culex* sp. mosquitoes, bird to bird contact, or via fomites (inanimate objects). The disease is associated with *Culex* sp. mosquito populations, thus the disease is seen more frequently in the summer months. Avian pox can have focal population recruitment implications in wet spring and summer periods (Forrester and Spalding, 2003). Additionally, viruses including lymphoproliferative neoplasms due to oncogenic viruses such as lymphoproliferative disease (LD) and reticuloendotheliosis (RE) viruses have been found in the eastern US; however, the population impacts of these viruses on turkeys are unknown (Forrester and Spalding, 2003).

Infectious sinusitis due to *Mycoplasma gallisepticum* causes a swollen head, often with purulent exudate within the sinuses. The causative bacteria are identified by culture or PCR and exposure of the pathogen can be detected by serology. There was one instance of the disease causing focal population implications in wild turkeys in Georgia (Hoffman et al., 1997). The other major bacterial diseases in wild turkeys include coligranuloma disease (*Escherichia coli*), avian cholera (*Pasturella multocida*) and salmonellosis (*Salmonella typhimurium*) (Davidson, 2006). Coligranuloma lesions often consist of variable sized, white-yellowish, often raised and/or ulcerated lesions on the surface of the liver, kidneys, and spleen. Fungal diseases include aspergillosis, candidiasis, and tail feather disease due to several species of fungi. Also a fungal dermatitis due to unknown etiology has been seen in birds in Florida (Forrester and Spalding, 2003). Aspergillosis is primarily due to *Aspergillus fumigates* which can lead to lung and air sac opacities with fungal hyphae apparent on histopathologic lesions. Aspergillosis has been infrequently reported in wild turkeys (Davidson et al., 1985).

Histomonas meleagridis is a protozoal enteric amoeba (liver form)/flagellate (intestinal form) that causes histomonosis (i.e. histomoniasis or blackhead). It is considered the most important parasitic disease for wild turkeys (Davidson et al, 1985; Forrester and Spalding, 2003). Gross lesions generally include target shaped foci of necrosis of variable size in the liver and the ceca are markedly thickened and the lumen is distended by a large amount of caseous necrotic (cheese-like mass of dead cells) and free blood (hemorrhagic) material consistent with cecal cores (McDougald, 2005). Chickens and pheasants (*Phasianus* spp.) are the natural hosts of the protozoa and rarely have clinical disease, but wild turkeys and Northern bobwhites (*Colinus virginianus*) can have severe disease.

Although coccidia caused by various *Eimeria* spp. including *Eimeria adenoides*, *E. gallopavonis*, *E. meleagrimitis*, *E. meleagriditis*, *E. innocua*, *E. subrotundra*, and *E. dispersa* infect wild turkeys clinical disease is usually associated with captive-reared birds. There is potential for disease in wild birds due to crowding at artificial feeders or bait piles.

The two most important nematodes for turkeys are *Heterakis gallinarum* and *Dispharynx nasuta*. *Heterakis gallinarum* is a cecal nematode, but more importantly it is the vector of *Histomonas meleagridis* and the protozoa can be found in the ovum of the nematode. *D.*

nasuta causes proventriculitis since the nematode head penetrates the lamina propria of the proventriculus leading to immune response resulting in swelling, ulceration, inflammatory infiltrates, caseous necrosis, hemorrhage, and destruction of proventricular glands. Infected birds are often listless, thin, and have ruffled feathers (Forrester and Spalding, 2003). The nematodes are generally found easily on necropsy. *Syngamus trachea* associated respiratory disease due to parasite infection of trachea has been reported in turkeys, but it is more common in captive reared birds (Davidson, 2006).

Our goal in this study was to investigate the various diseases circulating in hunter-killed birds in the region where turkeys have been reported as less abundant as well as perform a laboratory study investigating poultry litter as a source of pathogens for turkeys. Specifically, our goals were to:

1) Perform post-mortem examination of tissue sections collected from hunter-killed wild turkeys from the southern portions of Lawrence, Giles, Lincoln, and Wayne Counties (experimental area) to determine what lesions and potential disease agents are present. In addition perform select serological testing to determine exposure to various infectious diseases.

2) Perform similar testing on hunter-killed birds from Maury, Lewis, and Bedford counties (control area).

3) Determine if birds from experimental areas have increased prevalence of various infectious diseases.

4) Expose turkeys to poultry litter in a laboratory setting to determine if litter is associated with wild turkey morbidity and/or mortality.

Methods and Materials <u>Examination of hunter-killed birds</u>

In 2014 and 2015 we examined hunter-killed turkeys from the aforementioned counties for gross lesions. Birds were examined for gross lesions and select tissue samples, when available, including heart, lung, skin, brain, eyes, and kidneys, intestines, ventriculus, spleen, trachea, and esophagus were acquired and fixed in 10% formalin, embedded in paraffin, and thin sections stained with hematoxylin and eosin for histological analysis. PCR testing was performed on cecal tissue sections that had lesions suggestive of *Histomonas* using primers Histo 18S forward and reverse targeting a 209 bp (base pair) portion of the 18S short subunit of the ribosomal RNA (rRNA; Huber et al., 2005). Amplicons from positive PCR reactions were submitted to the University of Tennessee's molecular sequencing laboratory to obtain nucleotide sequences. Resultant sequences were aligned and subjected to a BLAST (Basic Local Alignment Search Tool) search in GenBank (http://blast.ncbi.nlm.nih.gov/Blast.cgi) to determine the closest match in the GenBank nucleotide library. In addition, when available, serum was collected from the birds and used to examine for exposure to AIV, NCDV, and *Mycoplasma* spp.

Laboratory Experiment with Poultry Litter

Forty, day-old, chicks purchased from a commercial propagator of eastern wild turkey (Stromberg's Chicks and Gamebirds Unlimited, Pine River, MN) were reared at the University of Tennessee animal facilities. The chicks were reared in incubators. At three weeks of age, each bird was bled, given a unique wing band, weighed, and transferred to floor pens at day 21. Due to difficulty in securing litter, the poults remained in the floor pen on clean litter for an extra 3 weeks. Once the poultry litter was collected from a commercial poultry farm in Lawrence County, Tennessee it was placed in six separate floor pens and four poults were placed in each of the six litter treatments for a total of 24 treatment birds. The poultry litter contained shavings, fecal material, poultry feathers and hundreds of thousands arthropods (Figure 2). Twelve control turkeys (3 pens of 4 birds) were placed on clean commercially purchased wood shavings in a room separate from the experimental birds. All turkeys were fed the same diet consisting of game bird starter. Turkeys remained on litter for 15 days, when they were euthanized, necropsied, blood collected, and tissues obtained for PCR and histological testing. One experimental bird (#96) was euthanized on day 13 due to severe lethargy and necropsied. Sections of liver and cecum from this bird was used for PCR testing to amplify DNA of *H. meleagridis*. Similarly, cecal contents were inoculated into Dwyer's media, which is used to propagate *H. meleagridis*, incubated at 40C and examined daily by light microscopy for microorganisms. Serological testing for select disease agents (NCDV, AIV and *Mycoplasma*) was performed on blood collected after exposure to litter.

Results: During the 2014 and 2015 spring turkey seasons, 106 and 112 hunter-killed wild turkeys were examined, respectively, for a total of 218 wild turkeys originating from multiple experimental and control counties in middle Tennessee being examined. Serological testing for AIV, NCDV, and *Mycoplasma* was performed. In total, 2 birds were ELISA-positive and one bird was inconclusive for AIV; 53 birds were ELISA-positive for NCDV; and 16 birds were ELISA-positive for *Mycoplasma* spp. bacteria (Tables 1 and 3). The serological test is unable to distinguish low path from high path AIV; however, no pulmonary lesions were observed in the turkeys that were seropositive for AIV, which suggests they were exposed to low path avian influenza viruses. Important histological findings of hunter-killed turkeys from 2014 included enteritis, typhlitis (cecal inflammation), various granulomas within organs, and lymphoid hyperplasia among eight birds; all from experimental counties. Histological lesions from 2015 hunter-killed turkeys included marked to severe typhlitis in 52 (46%) of turkeys and moderate typhlitis in another 23 (21%) of birds that originated from both experimental and control counties (45 from experimental counties and 30 from control counties); mild to marked

bronchointerstitial pneumonia in three birds and focal pulmonary granulomas in two birds. Mild to moderate periportal hepatitis was noted in fifteen birds.

PCR testing of cecal tissue from turkeys with corresponding lesions suggestive of histomonosis disclosed that three birds have evidence of *H. meleagridis* DNA via sequence and BLAST analysis; however, we were not able to obtain the confirmatory overlapping sequences from the PCR products and repeated DNA cloning was not successful. The birds with evidence of *H. meleagridis* DNA, in conjunction with lesions suggestive of histomonosis, are shown in Tables 2 and 3.

In the laboratory study involving poultry litter, one of 24 of the experimental birds was euthanized due to severe lethargy on day 13 of the litter exposure trial. Necropsy findings disclosed liver and cecal lesions consistent with *H. meleagridis* (Figure 1), which was confirmed by histological, culture, and PCR testing. Gross lesions were not seen in any other experimental or control birds. Histological analysis of birds disclosed mild to moderate inflammatory infiltrates in the cecum and liver from both experimental and control birds. All birds with lesions were tested for *H. meleagridis* by PCR. Five birds (including the bird above that died on day 13) were PCR positive as indicated by a band on the agarose gel. Of these five, only two birds were confirmed to have *H. meleagridis* by obtaining useable sequences. The two *H. meleagridis* sequence-positive birds were experimental bird #96 (which died on day 13) and experimental bird #86 which survived to termination of the study. Control birds with cecal lesions were PCR negative for *H. meleagridis*. Serum samples from all birds were ELISA-negative for AIV, NCDV, and *Mycoplasma* spp.

Discussion and Conclusions: Although serological evidence of AIV, NCDV, and *Mycoplasma* spp. exposure was detected in multiple hunter-killed birds during the two-year study, associated lesions were not detected. These findings suggest that the serological results do not correlate with clinical disease but instead suggest previous exposure. In this study, 24.3% (n=53) of examined turkeys were seropositive for NCDV. A study examining wild turkeys in southern Georgia, in regions where commercial poultry litter was spread, found that 13 (54%) of examined turkeys were seropositive to NCDV (Ingram et al., 2015). One potential reason for the relatively high levels of NCDV in our study as well as the Ingram et al. study is due to the potential ingestion of the commercial poultry NCDV vaccine strain in poultry litter.

The histological and molecular testing of the hunter-killed turkey health survey in combination with the laboratory experiment gives support that commercial poultry litter may be a source of *H. meleagridis* for wild turkeys. *Histomonas meleagridis* was detected by necropsy, parasite culture, and DNA sequencing in one of 24 laboratory turkeys exposed to litter from a commercial poultry house in Lawrence County, Tennessee (Figure 1). A second experimental bird was sequence positive for *H. meleagridis*. Furthermore, results indicate *H.*

meleagridis DNA was found in the cecal tissue of three hunter-killed birds from the experimental counties (Tables 2 and 3). These birds had lesions suggestive of *H. meleagridis* infection based on histological analysis. Unfortunately we were not able to obtain overlapping *H. meleagridis* sequences for these hunter-killed birds. Waters et al. (1994), examined the cecal contents from commercial poultry breeders, layers, and broilers in the southeastern United States and found *Heterakis gallinarum* to be most prevalent in the cecum of breeders, with 80% (n=24) of flocks infected; whereas, only 7% (n=2) and 33% (n=10) of broiler and layer flocks were positive for *H. gallinarum*, respectively. In addition, the authors also found 3 (75%) of *H. gallinarum* collected from commercial breeders were carriers of *H. meleagridis* based on bioassay results. The authors concluded that the litter from commercial poultry breeder and layer operations has the potential for transmission of histomonosis in areas where susceptible wild birds may be exposed. The litter used in our study was from a breeder facility in Lawrence County.

It is important to note that pathogens that are found in hunter-killed turkeys do not necessarily mean that these pathogens are causing mortality and perhaps even morbidity. Birds that are being taken by hunters are assumed to be exhibiting normal breeding behavior and are assumed to be in good physical condition. Thus, these hunter-killed birds are likely survivors of an infection or did not experience significant illness. If a hunter-killed bird was infected with a potentially fatal pathogen, the disease process would have been in the early stages since birds in late stage disease would not be exhibiting normal breeding behavior. This may be the situation with the three hunter-killed birds in which *H. meleagridis* DNA was found along with cecal inflammation. These findings suggest that these hunter-killed birds may have been experiencing early stage, subclinical effects of histomonosis. Hunter-killed birds serve more as sentinels of circulating disease within a population.

Our results suggest that PCR testing may not be the most sensitive diagnostic test to detect early stage infection of *H. meleagridis*. To this end, we are working to construct a sensitive and specific serological ELISA test to detect antibodies to *H. meleagridis*. Once constructed, the ELISA should be used to test serum samples from hunter-killed and litter study birds (if funding is available) which may indicate further *H. meleagridis* exposure in turkeys. In addition, further research on *H. meleagridis* prevalence, transmission, environmental persistence, and control measures is warranted. In particular we believe the laboratory bioassay study needs to be repeated for longer duration and at a larger scale to examine litter from multiple different poultry facilities from both within and outside the experimental region. In addition, the litter from these various poultry facilities, as well as the litter from the poultry facility used in this study, should be screened for various parasitic eggs of poultry and the arthropods within the litter examined for the presence of *H. meleagridis* DNA via PCR and sequencing. Telemetry studies, combining mortality investigations along with baseline health investigation of radio-collared birds, is also warranted to establish the role of disease as a mortality factor affecting populations of wild turkeys. Consideration should also be given to continued disease

surveillance for hunter-killed birds in the experimental regions and potentially expand the control region counties to obtain a more thorough baseline for wild turkey diseases and pathogen infection and/or exposure. These studies will all aid in further understanding whether disease (in association with or without poultry litter) may be responsible for the perceived turkey population decline.

References

Davidson, W. R., V. Nettles, C. E. Couvillion, and E. Howerth. 1985. Diseases diagnosed in wild turkeys (*Meleagris gallopavo*) of the southeastern United States. Journal of Wildlife Diseases 21: 386-390.

Davidson, WR. 2006. Wild turkeys. Pp. 253-273. *In* Field Manual of Wildlife Diseases in the southeastern United States. Southeastern Cooperative Wildlife Disease Study Press, Athens, GA.

Forrester, DJ, and MG Spalding. 2003. Wild turkeys. Pp. 558-569. *In* Parasites and Diseases in Wild Birds in Florida. University Press of Florida, Gainesville, FL.

Gerhold, R. W., C. M. Tate, S. E. Gibbs, D. G. Mead, A. B. Allison, and J. R. Fischer. 2007. Necropsy findings and arbovirus surveillance in mourning doves (*Zenaida macroura*) from the southeastern United States. Journal of Wildlife Diseases 43:129-35.

Hoffman, RW, MP Luttrell, WR Davidson, and DH Ley. 1997. Mycoplasmas in wild turkeys living in association with domestic fowl. Journal of Wildlife Diseases 33:526-535.

Huber, K., C. Chauve, and L. Zenner. Detection of *Histomonas meleagridis* in turkey cecal droppings by PCR amplification of the small subunit ribosomal DNA sequence. Veterinary Parasitology 131: 311-316.

Ingram, D. R., D. L. Miller, C. A. Baldwin, J. Turco, and J. M. Lockhart. 2015. Serological survey of wild turkeys (*Meleagris gallopavo*) and evidence of exposure to avian encephalomyelitis virus in Georgia and Florida. Journal of Wildlife Diseases 51: 374-379.

McDougald, L. R. 2005. Blackhead disease (histomoniasis) in poultry: a critical review. Avian Diseases 49: 462-476.

Waters, C. W., L. D. Hall, W. R. Davidson, E. A. Rollor, K. A. Lee. 1994. Status of commercial and noncommercial chickens as potential sources of histomoniasis among wild turkeys. Wildlife Society Bulletin 22: 43-49.

Figure 1. Clinical signs and lesions from bird # 96 from a laboratory study involving commercial breed of wild turkeys which were exposed to commercial poultry litter from a Lawrence Co., Tennessee breeder facility. On day 13 of the experiment, the bird had severe lethargy and depression (A) and sulfur-yellow droppings (B). Bird was euthanized and gross necropsy performed. Classic lesions of histomonosis including cecal distention and necrosis (C) and liver target lesions (D) were observed. Arrows point to inflamed and distended cecum (C) or two of the many liver target lesions (D). Diagnosis of histomonosis was confirmed by microscopic analysis, protozoal culture, and PCR followed by DNA sequencing.

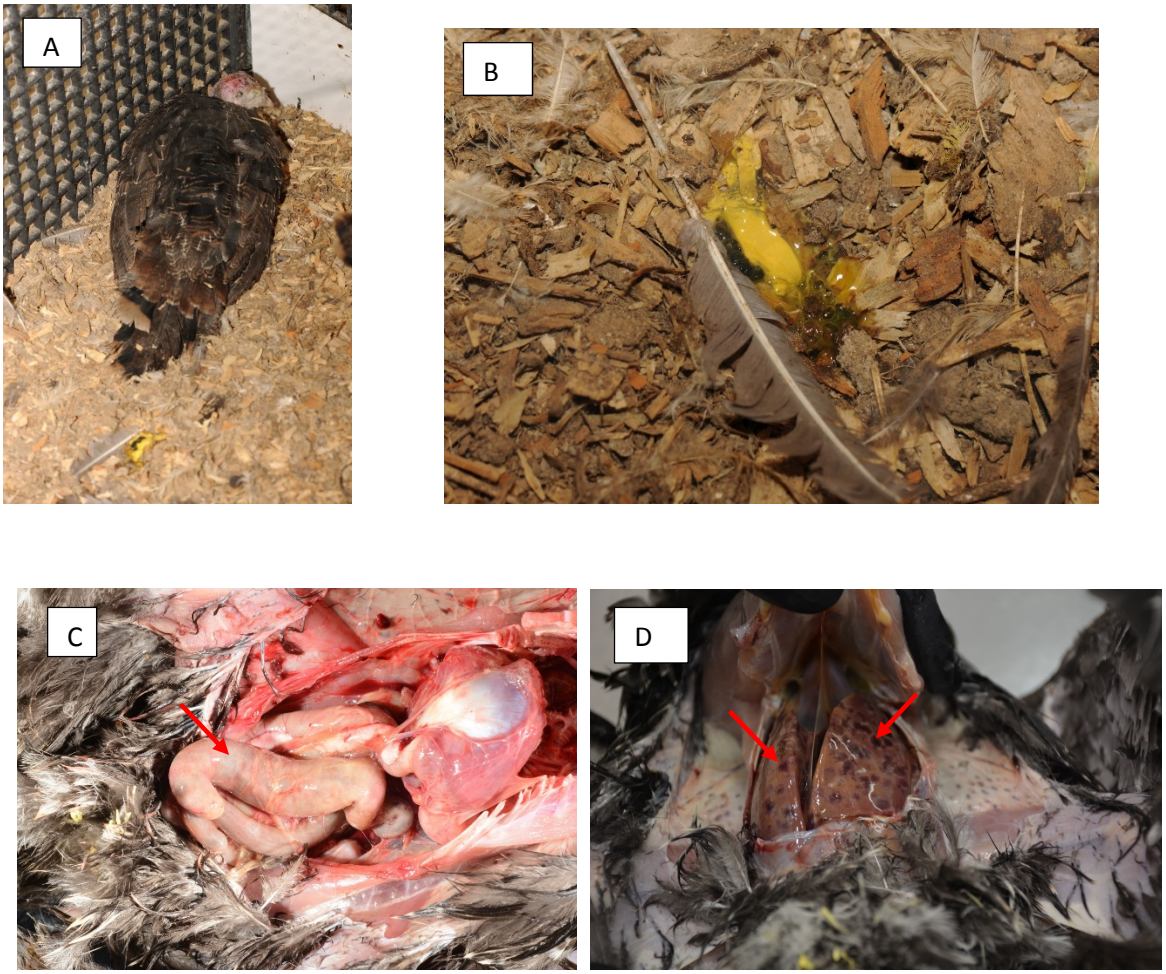

Figure 2. Various arthropods observerd in the commerical poultry litter from the Lawerence county poultry facility used in the bioassay trials. Note larger black arthropods (thin blue arrow) as well as smaller arthropods (thick green arrows). The majority of arthropods were identified as darkling beetles (Tenebrionidae) with a smaller proportion being hister beetles (Histeridae) or ground beetles (Carabidae). Research is needed to determine if arthropods can be a transport host for *H. meleagridis*.

Table 1. Breakdown of serologically positive wild turkey serum from 2014 and 2015 hunter-killed turkeys. ELISA testing was performed at the University of Tennessee's Immunology Laboratory.

	2014 Hunter-killed turkeys serological results			
Disease agent	Number of birds serologically positive	Counties birds originated	Percent of birds from experimental counties	Lesions associated with serological results
Avian influenza	1 (inconclusive)	Giles	100%	None
New Castle disease	52	Giles, Lincoln, Lawrence, Bedford, Wayne, Lewis, Maury, Unknown	67.3%	none
Mycoplasma	13	Giles, Lincoln, Lawrence, Bedford, Wayne, Maury, Unknown	61.5%	None
	2015 Hunter-killed turkeys serological results			
Disease agent	Number of birds serologically positive	Counties birds originated	Percent of birds from experimental counties	Lesions associated with serological results
Avian influenza	2	Maury	0%	None
New Castle disease	1	Giles	100%	None
Mycoplasma	3	Giles	100%	None

Table 2. Results of PCR testing of hunter-killed birds from middle Tennessee with DNA evidence of *Histomonas meleagridis* infection. Samples had histological evidence of lesions suggestive of *H. meleagridis* infection.

UT internal ID#	TWRA ID #	County of origin	% Identity to *Histomonas meleagridis* in GenBank	Accession no. in GenBank with closest match to sequence
WITU 2014-2	LIBS 2	Giles	88%	EU647887
WITU 2014-9	LIBS 9	Lincoln	98%	EU647887
WITU 2015-45	Williamson-14	Giles	94%	EU647887

Table 3. Breakdown serology and PCR results by county of origin for 2014 and 2015 hunter-killed turkeys.

Experimental or Control	County of origin	Number of examined birds during 2014-2015	Percent of birds seropositive for Avian influenza	Percent of birds seropositive for New Castle disease	Percent of birds seropositive for *Mycoplasma* spp.	Percent of birds DNA sequence positive for *Histomonas*
Experimental	Giles	81	1(inconclusive)	18	5	2
	Lawrence	24	0	7	2	0
	Lincoln	6	0	2	1	1
	Wayne	28	0	9	3	0
Control	Bedford	17	0	2	2	0
	Lewis	4	0	2	0	0
	Maury	52	2	12	2	0
Unknown	Unknown	6	0	1	1	
Totals		218	2(+1 inconclusive)	53	16	3